Advances in World Medical Research, 2025, 1(1), 71-77
https://doi.org/10.71204/qbn44528

Analysis of 43 Cases of Difficulties in Removing Artificial Nasolacrimal Duct Stents after Implantation

Jiaxin Chen [1], Jinxin Chen [1], Licong Nie [1], Yonggang Liu [1,*]

[1] Eye Hospital, China Academy of Chinese Medical Sciences, Beijing 110000, China

*** Correspondence**:

Yonggang Liu

ygliu0208@163.com

Received: 15 April 2025/ Accepted: 16 May 2025/ Published online: 20 May 2025

Abstract

To explore the causes of difficulties in removing artificial nasolacrimal duct stents after implantation, analyze the bony structural characteristics of the nasolacrimal duct and its impaction causes, and study the structural features of the nasolacrimal duct under paranasal sinus CT, so as to provide references for clinical practice. The clinical data of 43 patients (44 sides) with difficulties in removing artificial nasolacrimal ducts after implantation from October 2018 to June 2022 were retrospectively analyzed, including the patients' age, concurrent diseases, catheterization time, etc. The removal of the nasolacrimal duct was performed under nasal endoscopy, and 40 patients underwent paranasal sinus CT examination. Among the 44 cases of difficult tube removal, 43 cases were successfully removed, and 1 case was not removed. The reasons for the difficulties included the detachment or inversion of the traction wire (30 cases), the impaction of the tube head ring (11 cases), the fracture of the nasolacrimal duct due to long - term catheterization (1 case), and suture fixation during the catheterization operation (1 case). The difficulties in removing artificial nasolacrimal duct stents are related to factors such as the position of the traction wire, the impaction of the tube body, the degeneration of the nasolacrimal duct, and nasal diseases. Feasible solutions were also explored. The bony structural characteristics of the nasolacrimal duct, such as narrowness, curvature, and the influence of surrounding bones, increase the difficulty of tube removal. The paranasal sinus CT of 40 cases can show that the structure of the some nasolacrimal duct is different from that of the normal nasolacrimal duct. The research suggests that clinicians should comprehensively consider various factors to optimize the treatment strategy, providing a reference for clinical surgeries.

Keywords: Artificial Nasolacrimal Duct; Difficulties in Tube Removal; Nasal Endoscopy; Bony Structure; Paranasal Sinus CT

1. Introduction

Artificial nasolacrimal duct implantation surgery is a common treatment for lacrimal duct stenosis caused by chronic dacryocystitis and other reasons. It can make the lacrimal duct unobstructed and relieve symptoms such as epiphora, inflammation, and empyema (Nitin et al., 2022; Xie et al., 2017; Kim et al., 2007; Farat et al., 2021; Fayet et al., 2021). At an appropriate time after nasolacrimal duct implantation, if the function of the lacrimal duct returns to normal, in order to reduce complications and prevent the aging of the nasolacrimal duct, the artificial nasolacrimal duct needs to be removed (Karaca et al., 2019; Deosthale et al., 2023). The difficulties in removing the nasolacrimal duct may be related to multiple factors. This article analyzes and summarizes the cases of difficult nasolacrimal duct removal in our department as follows.

2. Materials and Methods

A retrospective analysis was performed on 43 cases (44 sides) of patients who came to our department with difficulties in removing artificial nasolacrimal ducts after implantation from October 2018 to June 2022. The patients' ages ranged from 23 to 72 years old, with an average age of 43 ± 8.1 years old. There were 23 cases with rhinitis, 12 cases with sinusitis, 20 cases with nasal septum deviation, and 33 cases with inferior turbinate hypertrophy.

The catheterization time of the artificial nasolacrimal duct ranged from 3 months to 30 years. Three types of catheters were involved, namely silicone - material nasolacrimal ducts, metal - material nasolacrimal ducts, and artificial synthetic polymer nasolacrimal ducts. The catheterization methods included traction through the lacrimal punctum and retrograde implantation through the nose, with standardized lacrimal duct irrigation (Figure 1).

The removal of the nasolacrimal duct was performed under nasal endoscopy in the otolaryngology department. The nasal cavity was contracted to fully expose the inferior meatus. The tail end of the artificial nasolacrimal duct in the inferior meatus was searched for under a 0 - degree endoscope, and it was clamped and removed with alligator forceps. During the tube - removal process, the force and direction were adjusted according to the resistance (Figure 2). According to the increasing difficulty of tube removal, there were the following four situations: ① The traction wire at the tail end of the nasolacrimal duct fell off or drooped backward, and the tube wall was not impacted. It could be clamped and removed smoothly; ② The tube head or tube body was impacted with resistance. The impacted ring of the nasolacrimal duct was pulled to the nasal meatus, and the ring was cut and removed; ③ The nasolacrimal duct became deformed and broken due to long - term catheterization, and it was removed in segments (Figure 3).

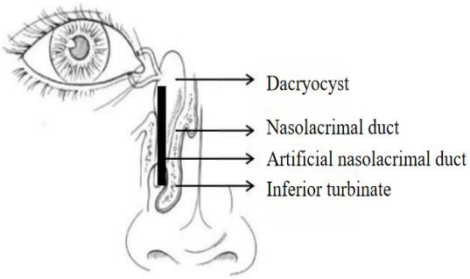

Figure 1. Schematic diagram of nasolacrimal duct implantation



Figure 2. Schematic diagram of nasolacrimal duct removal



Figure 3. Schematic diagram of removal after nasolacrimal duct rupture

3. Results

Among the 44 cases of difficult tube removal of the artificial nasolacrimal duct, 43 cases were successfully removed, and 1 case was not removed. In 28 cases, the traction wire at the end of the nasolacrimal duct fell off, and it could not be directly removed through the nostril. It was removed under endoscopy. In 2 cases, the traction wire at the end of the nasolacrimal duct drooped backward to the posterior nostril and could not be directly removed through the anterior nostril. It was removed under endoscopy. In 11 cases, the ring at the head of the nasolacrimal duct was impacted and was removed after being cut under endoscopy. In 1 case, the tube body of the nasolacrimal duct that had been catheterized for more than 30 years was broken into 3 segments and was removed under endoscopy. In 1 case, the nasolacrimal duct was sutured and fixed during the catheterization operation, and it could not be removed through the nose. It was removed by incising the lacrimal punctum.

4. Discussion

4.1. Causes of Difficult Tube Removal and Feasible Solutions

The removal of the nasolacrimal duct often faces various challenges in clinical practice. In this study, the removal of the nasolacrimal duct was mainly related to the position of the traction wire, the impaction of the tube body, and the fracture of the nasolacrimal duct due to degeneration. In this study, in 28 cases, the traction wire fell off, and in 2 cases, it drooped backward to the posterior nostril, making it impossible to directly remove the tube through the nostril. This was related to the catheterization time and operation. Long - term catheterization was likely to cause the traction wire to loosen, and improper operation might also damage the traction wire. However, a change in the position of the traction suture does not directly lead to difficulties in removing the nasolacrimal duct.In 11 cases, the ring at the head of the nasolacrimal duct was impacted with resistance, resulting in difficulties in tube removal. Most patients had nasal diseases, which also affected the removal of the nasolacrimal duct. In 1 case, the nasolacrimal duct that had been catheterized for more than 30 years was broken. Due to long - term catheterization, the material of

the nasolacrimal duct aged, and with the erosion of tears and tissue friction, its structure was damaged, increasing the difficulty of tube removal. Previous studies have shown that the nasolacrimal duct itself can cause granulation hyperplasia of the surrounding soft tissues and is prone to adhere to lacrimal duct secretions, increasing the difficulty of removal, which is consistent with the viewpoints of this study (Deosthale et al., 2023).Among the 43 patients, there were 23 cases with rhinitis, 12 cases with sinusitis, 20 cases with nasal septum deviation, and 33 cases with inferior turbinate hypertrophy. These diseases could cause swelling of the nasal mucosa, increased secretions, change the micro - environment around the nasolacrimal duct, affect the operation field of tube removal, and might also cause the nasolacrimal duct to be compressed, deformed, and adhered and impacted (Schleimer, 2017).

Removing the nasolacrimal duct within an appropriate time can prevent complications and material aging. Some studies have also shown that the implantation of artificial nasolacrimal duct stents can cause changes in the position of the eyelid (Vu et al., 2022). At present, the use of new biodegradable nasolacrimal ducts can reduce complications, but the long - term efficacy is still controversial (Zhan et al., 2017). If preparations with anti - inflammatory and immunosuppressive effects are used, such as ophthalmic ointment and low - dose mitomycin used by previous teams, it may reduce the possibility of difficult removal (Masoomian et al., 2021).

4.2. Analysis of the Bony Structural Characteristics of the Nasolacrimal Duct and its Impaction Causes

The physiological stenosis, curved course, non - uniform thickness of the nasolacrimal duct, and excessive insertion depth of the nasolacrimal duct are the causes of impaction during difficult tube removal. Its course is not only curved, but also its diameter is not uniform. It is usually the widest at the lacrimal sac and gradually becomes thinner when passing through the maxilla. This feature needs to be paid special attention to during tube removal (Ali, 2023).

In this study, the impaction during the removal of the nasolacrimal duct in 11 cases might be due to individual anatomical variations, resulting from the special structural problem that the ring at the head of the nasolacrimal duct is larger than the lumen of the human nasolacrimal duct. However, impaction is not only a problem of the structure of the tube head of the nasolacrimal duct, but also related to anatomical depth, physiological stenosis, improper catheterization, and interference from surrounding tissues. If the angle and position are inaccurate during catheterization, impaction is likely to occur.Some studies believe that primary acquired nasolacrimal duct obstruction can lead to changes in the thickness of the periosteum and fibrosis, which may also be one of the causes of impaction during the removal of the artificial nasolacrimal duct (Ali, 2021). Long - term inflammatory stimulation can cause thickening and adhesion of the soft tissues around the artificial nasolacrimal duct, also resulting in impaction of the nasolacrimal duct (Yazici et al., 2002; Prasad & Ghosh, 2020; Orsolini et al., 2020).

4.3. Analysis and Characteristics of the Nasolacrimal Duct Structure in 40 Cases of Paranasal Sinus CT

In 12 patients with a history of sinusitis surgery, the mucosa in the paranasal sinuses was thickened, showing a soft - tissue density shadow. In a small number of patients, the bones around

the nasolacrimal duct were blurred and thickened due to inflammation. On CT, it was manifested as the dilation of the nasolacrimal duct, increased density in the lumen, and the spread of inflammation in the paranasal sinuses to the surrounding area of the nasolacrimal duct, indicating that sinusitis might cause inflammation and adhesion, affecting the structure and function of the nasolacrimal duct (Desai et al., 2022; Campos-Navarro et al., 2023). In 23 patients with a history of rhinitis surgery, there were no obvious changes in the paranasal sinus CT. In 20 patients with a history of nasal septum deviation surgery, the paranasal sinus CT showed that the deviated part of the nasal septum compressed the ipsilateral nasal cavity structure, causing different displacements and deformations of the attachment of the nasolacrimal duct on the lateral wall of the nasal cavity due to different degrees of compression. In 33 cases with inferior turbinate hypertrophy, the CT suggested that part of the nasolacrimal duct was locally compressed and deformed.

Author Contributions:

Jiaxin Chen and Yonggang Liu designed the work; Jinxin Chen and Nie Licong contributed to the acquisition, analysis, and interpretation of data; Jiaxin Chen and Yonggang Liu wrote the main manuscript and prepared all the figures. Jiaxin Chen and Yonggang Liu revised the manuscript. All authors reviewed the manuscript.

Funding:

This work was supported by the grant of Project in Eye Hospital China Academy of Chinese Medical Science (No.202015/No.202026), Central High-Level Traditional Chinese Medicine Hospital Project of eye Hospital China Academy of Chinese medical science (No.GSP5-36/No.GSP5-80), Fundamental Research Funds for the Central Public Welfare Research Institutes No. ZZ17-XRZ-085).

Institutional Review Board Statement:

The studies were reviewed and approved by the Ethics Committee of the Eye Hospital of the China Academy of Chinese Medical Sciences.

Informed Consent Statement:

Written informed consent was obtained from all participants involved in this study, including consent for the publication of their clinical information and any accompanying images, where applicable.

Data Availability Statement:

Not applicable.

Acknowledgments:

The authors acknowledge for the support and technical comments of all reviewers.

Conflict of Interest:

The authors declare no conflict of interest.

References

Ali, M. J. (2023). Etiopathogenesis of primary acquired nasolacrimal duct obstruction (PANDO). Progress in Retinal and Eye Research, 96, 101193.

Ali, M. J., Mishra, D. K., & Bothra, N. (2021). Lacrimal fossa bony changes in chronic primary acquired nasolacrimal duct obstruction and acute dacryocystitis. Current Eye Research, 46(8), 1132-1136.

Campos-Navarro, L. A., Ibarra-Macari, M. E., Barrón-Campos, A. C., Moreno-Martínez, J. M., & Almeyda-Farfán, J. A. (2023). Hallazgos nasosinusales por tomografía computada en dacriocistitis crónica pediátrica. Cirugía y cirujanos, 91(1), 87-93.

Deosthale, N., Garikapati, P., Choudhary, S., Khadakkar, S., Deshpande, A., Mangade, S., & Dhote, K. (2023). Surgical Outcome of Endoscopic Dacryocystorhinostomy with and Without Prolene Stent in Chronic Dacryocystitis: A Randomized Controlled Trial. Indian Journal of Otolaryngology and Head & Neck Surgery, 75(4), 3443-3448.

Desai, A. B., Vibhute, P., & Bhatt, A. A. (2022). Obliterative sinusitis: an underreported clinical entity. Clinical Imaging, 81, 72-78.

Farat, J. G., Schellini, S. A., Dib, R. E., Santos, F. G. D., Meneghim, R. L. F. S., & Jorge, E. C. (2021). Probing for congenital nasolacrimal duct obstruction: a systematic review and meta-analysis of randomized clinical trials. Arquivos Brasileiros de Oftalmologia, 84(1), 91-98.

Fayet, B., Racy, E., Ruban, J. M., Katowitz, J. A., Katowitz, W. R., & Brémond-Gignac, D. (2021). Preloaded Monoka (Lacrijet) and congenital nasolacrimal duct obstruction: initial results. Journal Français d'Ophtalmologie, 44(5), 670-679.

Karaca, U., Genc, H., & Usta, G. (2019). Canalicular laceration (cheese wiring) with a silicone tube after endoscopic dacryocystorhinostomy: when to remove the tube?. GMS ophthalmology cases, 9, 31728262.

Kim, N. J., Kim, J. H., Hwang, S. W., Choung, H. K., Lee, Y. J., & Khwarg, S. I. (2007). Lacrimal silicone intubation for anatomically successful but functionally failed external dacryocystorhinostomy. Korean Journal of Ophthalmology, 21(2), 70-73.

Masoomian, B., Eshraghi, B., Latifi, G., & Esfandiari, H. (2021). Efficacy of probing adjunctive with low-dose mitomycin-C irrigation for the treatment of epiphora in adults with nasolacrimal duct stenosis. Taiwan Journal of Ophthalmology China, 11(3), 287-291.

Nitin, T., Uddin, S., & Paul, G. (2022). Endonasal Endoscopic Dacryocystorhinostomy with and Without Stents−A Comparative Study. Indian Journal of Otolaryngology and Head & Neck Surgery, 74(Suppl 2), 1433-1441.

Orsolini, M. J., Schellini, S. A., Souza Meneguim, R. L. F., & Catâneo, A. J. M. (2020). Success of endoscopic dacryocystorhinostomy with or without stents: systematic review and meta-analysis. Orbit, 39(4), 258-265.

Prasad, B. K., & Ghosh, K. K. (2020). Evaluation and comparison of the outcomes of endoscopic dacryocystorhinostomy with and without silicone stent. Bengal Journal of Otolaryngology and Head Neck Surgery, 28(3), 221-227.

Schleimer, R. P. (2017). Immunopathogenesis of chronic rhinosinusitis and nasal polyposis. Annual Review of Pathology: Mechanisms of Disease, 12(1), 331-357.

Vu, Q. A., Youn, J. M., & Baek, S. (2022). Changes in Eyelid Position Following Silicone Tube Insertion and Removal in Dacryocystorhinostomy. Journal of Craniofacial Surgery, 33(3), e223-e226.

Xie, C., Zhang, L., Liu, Y., Ma, H., & Li, S. (2017). Comparing the success rate of dacryocystorhinostomy with and without silicone intubation: a trial sequential analysis of randomized control trials. Scientific reports, 7(1), 1936.

Yazici, Z., Yazici, B., Parlak, M., Tuncel, E., & Ertürk, H. (2002). Treatment of nasolacrimal duct obstruction with polyurethane stent placement: long-term results. American Journal of Roentgenology, 179(2), 491-494.

Zhan, X., Guo, X., Liu, R., Hu, W., Zhang, L., & Xiang, N. (2017). Intervention using a novel biodegradable hollow stent containing polylactic acid-polyprolactone-polyethylene glycol complexes against lacrimal duct obstruction disease. PLoS One, 12(6), e0178679.