Advances in World Medical Research, 2025, 1(1), 50-60
https://doi.org/10.71204/7agtqd88

Scleritis Caused by Eosinophilic Granulomatosis with Polyangiitis: A Case Report

Wenbo Hou [1,*], Xin Li [1], Xuguang Sun [2]

[1] DepartmentIIof Ophthalmology, The Eye Hospital, China Academy Of Chinese Medical Sciences, Beijing 100040, China

[2] Department of Ocular Microbiology, Beijing Institute of Ophthalmology, Beijing Tongren Hospital, Capital Medical University, Beijing 100730, China

*** Correspondence**:

Wenbo Hou

susie2001@126.com

Received: 10 April 2025/ Accepted: 12 May 2025/ Published online: 20 May 2025

Abstract

To report a case of an 81-year-old female with scleritis due to eosinophilic granulomatosis with polyangiitis (EGPA) and emphasize the importance of accurate diagnosis and appropriate management. The patient's initial symptoms, including scleritis and systemic manifestations such as recurrent fever, were observed. Laboratory tests, imaging studies, ANCA testing, and bone marrow biopsy were performed for diagnosis. Treatment with methylprednisolone and cyclophosphamide was administered, and the response was monitored by observing the resolution of scleritis and normalization of blood parameters. The patient was initially misdiagnosed. However, through comprehensive examinations, the EGPA diagnosis was confirmed. The treatment was effective, with the scleritis being resolved and blood parameters returning to normal. EGPA is a rare ANCA-associated vasculitis with complex and non-specific manifestations. ANCA is a significant biomarker, and comprehensive laboratory testing is crucial for accurate diagnosis. Treatment consists of induction and maintenance phases. Ophthalmologists should be aware of the possibility of systemic autoimmune diseases in scleritis patients, especially those with eosinophilia and systemic symptoms, and cooperate with internal medicine specialists for optimal patient management.

Keywords: Eosinophilic Granulomatosis with Polyangiitis; ANCA; Scleritis; Autoimmune Disease; ANCA-associated Vasculitis

1. Introduction

Eosinophilic Granulomatosis with polyangiitis (EGPA), formerly known as Churg-Strauss syndrome, is the rarest form of antineutrophil cytoplasmic antibody (ANCA)-associated vasculitis

(AAV) (Churg & Strauss, 1951; Jennette et al., 2012; Kitching et al., 2020). It is characterized by eosinophil-rich granulomatous inflammation and vasculitis affecting small to medium-sized vessels, with an annual prevalence ranging from 10.7 to 17.8 cases per million[4]. As an uncommon disease, EGPA is distinguished by a wide range of clinical symptoms that might change at different points in the disease's natural history. Systemic vasculitis frequently progresses quickly, and in about half of patients, systemic symptoms are accompanied by clinical signs of a vasculitis process, including purpura, scleritis, alveolar hemorrhage, extracapillary glomerulonephritis, and involvement of the peripheral nervous system (Furuta et al., 2019; Lutalo et al., 2014).

Since EGPA can progress to organ- or life-threatening diseases, we must be on the lookout for patients who have scleritis along with systemic symptoms, particularly those who have elevated eosinophils and ANCA levels. In this report, we present a case of scleritis caused by granulomatosis with EGPA, although the local features of scleritis in this case are not specific, the findings of pertinent tests can aid in the early diagnosis of EGPA.

2. Case Presentation

An 81-year-old female patient presented with the chief complaints of recurrent fever for half a year and redness in the right eye accompanied by decreased visual acuity for more than one month. The patient had a history of hypothyroidism and sinusitis in the past. In the recent half year, she had experienced fatigue, recurrent low fever, numbness in the limbs, and weight loss. She denied a family history of trauma and hereditary diseases.

At the time of consultation, the best corrected visual acuity (BCVA) of the right eye was 0.25, and the intraocular pressure was 15 mmHg (1 mmHg = 0.133 kPa). The sclera was congested with a dark red color (Figure 1), and the lens was opaque (C2N2PO). The optic disc in the fundus had a normal color and a clear border, with the cup-to-disc ratio (C/D) approximately 0.3 and the arteriovenous ratio (A:V) approximately 1:2. The reflection of the fovea centralis was unclear.



Figure 1. This is an anterior segment photograph of the patient taken at the time of presentation. The sclera is dark red with edema and there is a decrease in vision.

The results of auxiliary examinations were as follows:

(1) Blood routine: The white blood cell count (WBC) was 11.4 × 10^9/L (elevated), the percentage of neutrophils (NEUT%) was 78.6% (elevated), the percentage of lymphocytes (LYM%) was 9.6% (decreased), the neutrophil count (NEUT) was 8.96 × 10^9/L (elevated), and the eosinophil count was 0.53 × 10^9/L (elevated).

(2) Comprehensive biochemistry: The rheumatoid factor (RF) was 32.4 IU/ml, and the C-reactive protein (CRP) was 67.21 mg/L.

(3) Coagulation panel: The fibrinogen (Fib) was 4.6 g/L, the D-dimer was 1.8 mg/L, and the fibrinogen degradation products (FDP) were 7.1 mg/L.

(4) Seven items of thyroid function: Triiodothyronine (TT3) was 0.85 nmol/L, free triiodothyronine (FT3) was 2.66 pmol/L, thyroid-stimulating hormone (TSH) was 6.00 mIU/L, anti-thyroglobulin antibody (TG-Ab) was 222.4 IU/ml, and anti-thyroid peroxidase antibody (TPO-Ab) was 360.54 IU/ml.

(5) Screening for rheumatic immune diseases: Anti-centromere antibody (CENP-B) was 93.17 RU/ml.

(6) Detection of respiratory viruses: Antibodies to common respiratory viruses were all negative.

(7) Inflammatory panel: Interleukin-6 (IL-6) measurement was 25.5 pg/ml.

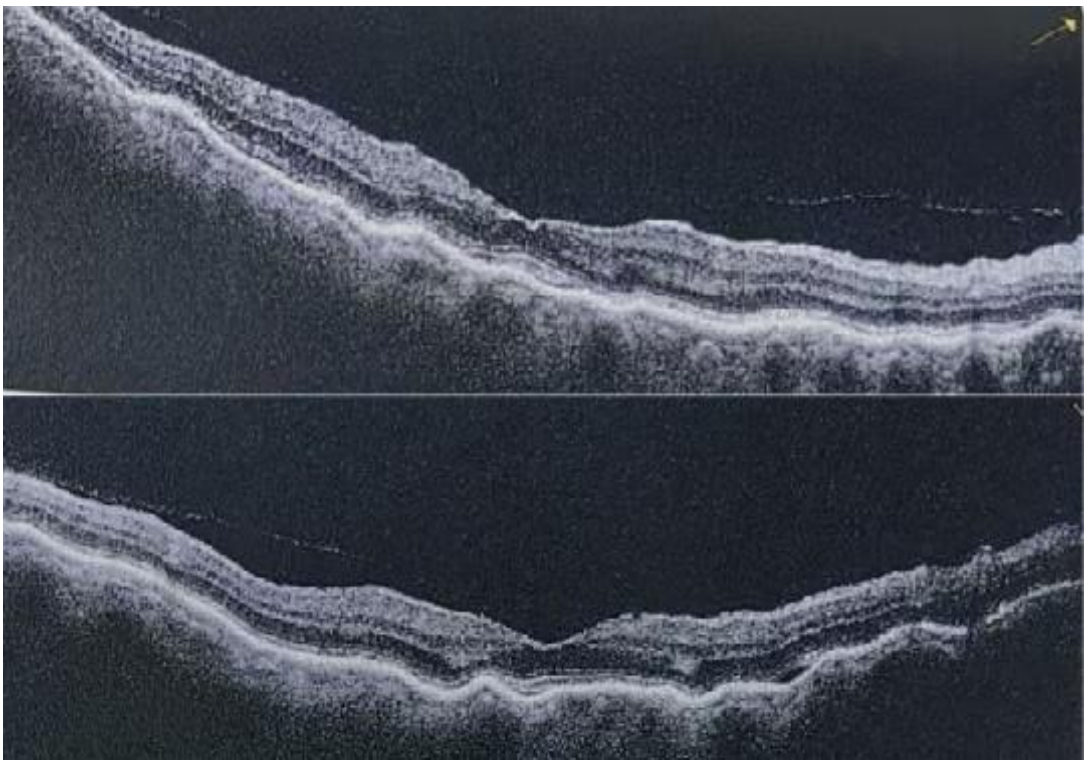

Figure 2. The patient was found to have a cuspidate wave-like folding of the choroid and retina in the macula by OCT examination.

(8) Tests for eight items of infectious diseases, hepatitis A antibody, and hepatitis E antibody were all negative.

(9) Electrocardiogram showed sinus rhythm, right ventricular conduction delay, moderate left axis deviation, and no other significant abnormalities.

(10) Optical coherence tomography (OCT) of both eyes: The choroid in the macular area was thickened, and there were wavy folds in the retina and choroid (Figure 2).

(11) Fluorescein fundus angiography (FFA) and indocyanine green angiography (ICGA) indicated choroidal edema in the right eye and scleritis in the right eye.

(12) Ocular B-ultrasound showed thickening of the right sclera with the "T" sign (Figure 3).

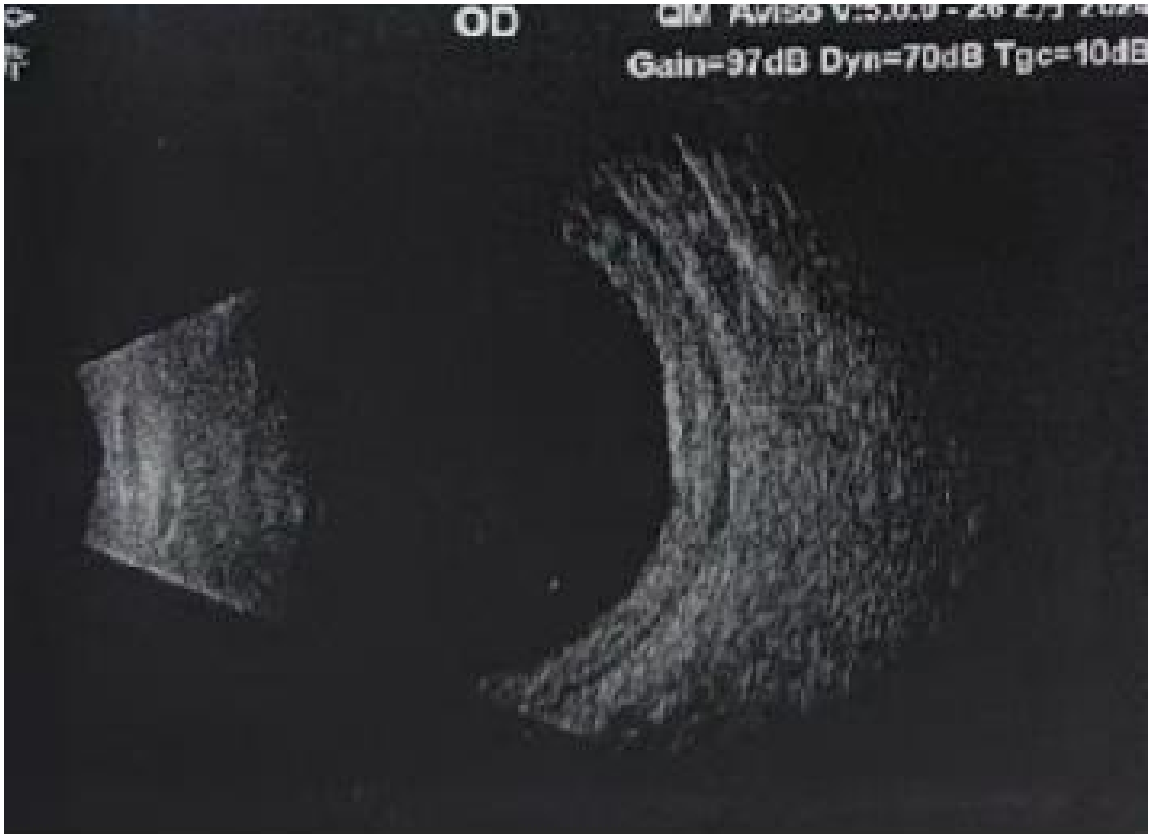

Figure 3. The patient presents with the classic "T-sign"

(13) Plain CT scan of the paranasal sinuses: The mucous membranes of the bilateral maxillary sinuses, part of the ethmoid sinuses, and sphenoid sinuses were thickened.

(14) Color Doppler ultrasound of organs and blood vessels throughout the body: There were no significant abnormalities in the liver, gallbladder, pancreas, and spleen; there were bilateral renal cysts; the uterus was in the postmenopausal state; the bilateral lower extremity arteries showed atherosclerotic changes accompanied by plaques. Echocardiography showed aortic valve regurgitation (mild), mitral and tricuspid valve regurgitation (mild), and decreased left ventricular diastolic function.

(15) Enhanced orbital MRI scan: The ring of the right eye was thickened with enhancement, and there were abnormal enhancements in the right lacrimal gland, right orbital apex, and posterior

ethmoid sinuses; there was partial empty sella turcica; there was a slight inflammation in the bilateral maxillary sinuses; and there was inflammation in the bilateral mastoid processes.

Based on the above examination results, the patient was diagnosed with scleritis in the right eye, sinusitis, and hypothyroidism. She was treated with prednisolone acetate eye drops, 6 times a day, tobramycin and dexamethasone eye ointment, once a night, pranoprofen eye drops, 4 times a day for the right eye, and retrobulbar injection of triamcinolone acetonide injection 20 mg + dexamethasone sodium phosphate injection 2.5 mg + lidocaine injection 0.5 ml for the right eye. Additionally, a trial treatment was carried out using Cefoperazone sodium 1.5g was administered intravenously, and Diclofenac sodium pills were taken orally on a daily basis. This regimen consisted of systemic antibiotics and nonsteroidal anti-inflammatory drugs due to the persistent uncertainty regarding the cause of the recurrent fever. After three weeks of treatment, the scleritis in the patient's right eye substantially subsided, and the visual acuity improved. The best corrected visual acuity of the right eye was 0.6. OCT reexamination showed that the choroidal folds had mostly disappeared, and the fever had abated. Subsequently, the patient was discharged. However, two weeks after discharge, the fever recurred, reaching a maximum of 39.2°C. Consequently, the patient was readmitted to the hospital. After being hospitalized again, laboratory examinations were conducted. It was found that the level of MPO-ANCA was 246.00 AU/ml (elevated), and the titer of P-ANCA was 1:20. Flow cytometry of bone marrow demonstrated an increased proportion of eosinophils. Bone marrow biopsy revealed that the bone marrow hyperplasia was generally normal, with the proliferation of granulocyte, erythrocyte, and megakaryocyte lineages accompanied by easily observable eosinophils (Figure 4). The screening results for bone marrow proliferative neoplasm (MPN) gene mutations were negative. No clonal abnormalities were detected in the bone marrow chromosome examination.

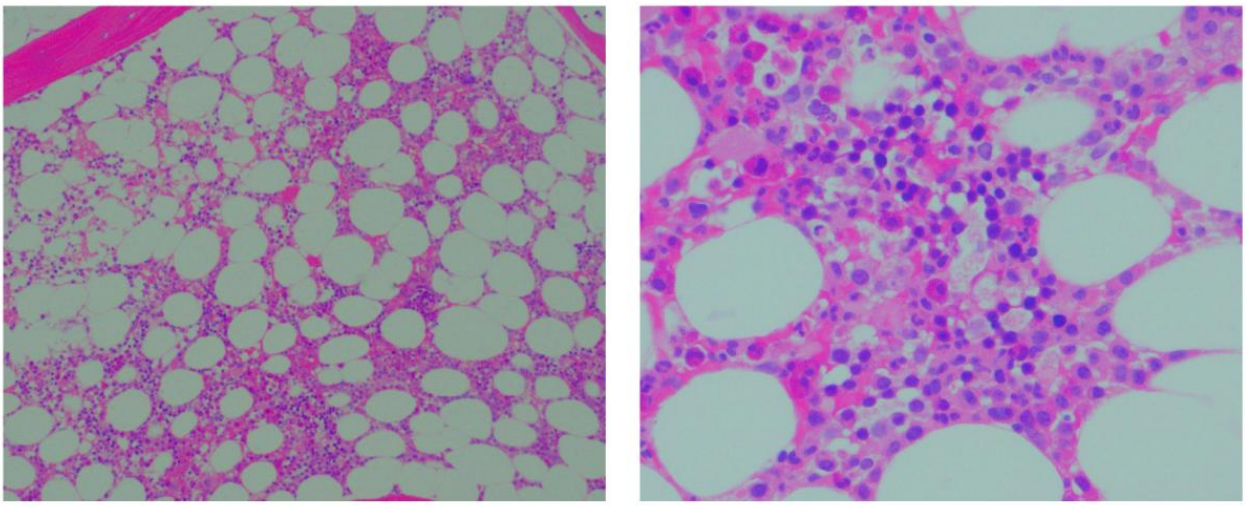

Figure 4. Bone marrow aspiration: There is a marked increase in the activity of bone marrow cell morphogenesis, with an increase in the proportion of granulocytes and an increase in the proportion of acidophilic granulocytes.

Based on the patient's past medical history, symptoms, physical signs, laboratory test results, and imaging findings, a diagnosis of eosinophilic granulomatous vasculitis (EGPA) was confirmed.

After the diagnosis was clear, methylprednisolone at a dose of 40 mg once daily was administered by intravenous infusion, combined with cyclophosphamide at a dose of 0.2 g every other day. In addition, low-molecular-weight heparin at a prophylactic dose was used for anticoagulation, and cotrimoxazole was given for infection prevention. After one month of treatment, the patient's systemic symptoms such as fever and fatigue completely disappeared, scleritis was completely cured, and both blood routine parameters and immune indexes returned to normal. The best corrected visual acuity (BCVA) of the right eye improved to 0.8, and no significant abnormalities were found in the ocular examination. Prednisolone tablets at a dose of 40 mg once daily and cyclophosphamide at a dose of 0.1 g every other day were used for maintenance treatment, along with liver protection and anticoagulation therapies. During the follow-up period, the patient's condition remained stable, and there was no recurrence.

3. Discussion

Scleritis is a relatively rare eye disease in clinical practice, accounting for only about 0.5% of all eye diseases. Its etiology is complex and not fully understood at present. It may be related to exogenous infection, endogenous infection, and autoimmune diseases (Vergouwen et al., 2020; Nevares et al., 2020). Scleritis can occur during the onset or before the onset of potentially fatal systemic autoimmune diseases, therefore, early diagnosis and treatment of scleritis, especially thorough screening for patients with systemic symptoms, is particularly important.

This case is an example of an autoimmune disease - eosinophilic granulomatous vasculitis (EGPA) causing scleritis. The patient initially presented with scleritis, but because the systemic symptoms were mild and presented only low-grade fever, the true underlying cause of the scleritis was not investigated.

EGPA is a rare clinical disease. The pathological changes mainly involve small and medium-sized blood vessels, manifesting as systemic necrotizing vasculitis, and it belongs to antineutrophil cytoplasmic antibody (ANCA)-associated vasculitis (AAV) (Churg & Strauss, 1951). It was first described by Churg and Strauss in 1951 (Churg & Strauss, 1951). It often presents initially with asthma, sinusitis, and eosinophilia. After an average period of 3 to 9 years, it progresses to the vasculitis stage, and the pathological changes can involve multiple tissues and organs throughout the body. Due to the lack of specificity in its clinical manifestations, it is prone to misdiagnosis and missed diagnosis (Szczeklik et al., 2011; Keogh et al., 2006).

Currently, there is no formal diagnostic criteria for EGPA. Historically, Lanham et al. published a set of diagnostic criteria in 1984, but it did not include ANCA testing and had poor sensitivity for a limited number of disease patients (Lanham et al., 1984). The 2012 revision of the Chapel Hill Consensus Conference (CHCC) vascular disease nomenclature classified EGPA as a disease characterized by eosinophilic and necrotizing granulomatous inflammation, typically involving the respiratory tract, with necrotizing vasculitis predominating, primarily affecting small to medium-sized vessels, and accompanied by asthma and eosinophilia (Jennette et al., 2013; Wechsler et al., 2017). Recently, a practical diagnostic criteria set was proposed by a joint working group supported by the European Respiratory Society (ERS) and Groupe d'Etudes et de Recherche sur les Maladies

Orphelines Pulmonaires (GERM'O'P), limiting the term EGPA to patients with positive ANCA tests or those with true vascular inflammation features (Cottin et al., 2016).

EGPA is usually divided into three overlapping stages: a prodromal period, which may last for several years, characterized by respiratory symptoms with asthma and sinusitis; the second stage, accompanied by an increase in blood eosinophils, tissue infiltration of eosinophils, and organ damage caused by eosinophils; and the third stage, characterized by systemic necrotizing vasculitis. Once diagnosed with EGPA, the clinical course can progress from an acute, self-limiting process to multi-organ dysfunction, with a high morbidity and mortality rate (Berti et al., 2020).

EGPA presented as heterogeneous clinical manifestations that may change at different stages of the natural course of the disease. Most patients have systemic symptoms such as fever, muscle and joint pain, and weight loss. Skin involvement manifests as purpura, subcutaneous nodules, urticaria, skin infarction, reticular purpura, and tense vesicles. The literature reports that 62% of patients with EGPA have cardiac involvement, but only 26% have clinical symptoms. Cardiac involvement is the leading cause of death in EGPA (Hazebroek et al., 2015). Peripheral neuropathy is the most important clinical manifestation of the vasculitis phase of EGPA, affecting about 2/3 of patients, and presents as multiple mononeuritis, affecting both motor and sensory nerves (Koike et al., 2012).

ANCA is an important vascular inflammation biomarker in EGPA. The positive rate of ANCA in granulomatous vasculitis and microscopic polyangiitis can reach 75%-95%. The positive rate of ANCA in EGPA is 30%-40%, mainly positive for p-ANCA and MPO-ANCA. The prognosis of EGPA is good, with a 7-year survival rate of 90%. MPO-ANCA positivity, peripheral blood eosinophilia $<3\times10^9$/L at diagnosis, and peripheral neuropathy may be risk factors for disease recurrence (Saku et al., 2018; Durel et al., 2016; Comarmond et al., 2013; Sinico et al., 2005; Moosig et al., 2013; Tsurikisawa et al., 2017). The levels of p-ANCA and MPO-ANCA in this case were significantly elevated, which led us to strongly suspect that the patient had EGPA. Additionally, the patient's persistent fever prompted a bone marrow biopsy, which ultimately confirmed the diagnosis of EGPA. ANCA-positive patients seem to be more likely to have vasculitis manifestations. Some studies have found that 43.4% of EGPA patients have ocular complications, some of which are caused by the use of steroids, such as steroid-induced cataract, and others may include neuro-ophthalmic diseases, persistent scleritis, uveitis, etc., which can cause acute damage to visual function, but there are cases of blindness due to this (Turk et al., 2021; Hinojosa-Azaola et al., 2019).

Therefore, in the future when encountering scleritis patients in clinical practice, especially those with scleritis accompanied by systemic abnormalities, a comprehensive screening and evaluation should be conducted to determine any non-ocular conditions related to the diagnosis. In the diagnostic workup of scleritis, a comprehensive hematological analysis is warranted. Complete blood count parameters, namely hemoglobin, platelet, and white blood cell counts, in conjunction with inflammatory biomarkers such as C-reactive protein (CRP) and erythrocyte sedimentation rate (ESR), possess significant value in signifying the existence of an underlying inflammatory cascade. Furthermore, the assessment of autoimmune serological markers is indispensable. Antinuclear antibody (ANA), extractable nuclear antigens (including anti-ds-DNA, anti-histone, anti-Smith, anti-Ro, anti-La, anti-Jo), rheumatoid factor (RF), complement levels (C3 and C4),

antiphospholipid antibodies, as well as the vasculitis autoimmune profile (encompassing c-ANCA, p-ANCA, atypical c-ANCA, atypical p-ANCA, myeloperoxidase p-ANCA, proteinase 3 c-ANCA, glomerular basement membrane antibody), are of crucial importance in formulating a definitive diagnosis of immune-mediated systemic vasculitis concomitant with scleritis. This comprehensive approach to laboratory testing aids in the accurate identification and classification of the disease, facilitating appropriate management strategies and improved patient outcomes.

The treatment of EGPA includes an induction phase and a maintenance phase. The former aims to relieve the disease, while the latter seeks to prevent recurrence. Prospective studies specifically targeting EGPA are rare, and most treatment recommendations for EGPA are directed at symptomatic treatment for specific affected organs. Patients with a confirmed diagnosis of EGPA should be treated with steroids and immunosuppressants as early as possible to improve prognosis (Raffray et al., 2020; Fujimoto et al., 2011). After disease control, steroids need to be tapered, but long-term use of immunosuppressants is still required to reduce the side effects of long-term high-dose steroids. In addition, close follow-up is needed to monitor the dynamic changes of ANCA titers and to detect recurrence of the disease as early as possible (Watanabe et al., 2023; Cottin et al., 2016). For local ocular lesions, in addition to systemic therapy, topical eye drops are more effective. As our understanding of ANCA-related small vessel vasculitis deepens, the diseases it causes in the field of ophthalmology will also be given greater attention.

This case reminds us that when scleritis is accompanied by fever and other systemic symptoms, a thorough physical examination should be performed to determine whether there is a systemic autoimmune disease. When the blood count shows an increase in eosinophils, it is important to perform additional tests, such as ANCA, to consider the possibility of EGPA. Ophthalmologists should be aware of the importance of consulting with internal medicine specialists.

Author Contributions:

Conceptualization, W. H., X. L., X. S.; methodology, W. H., X. L., X. S.; software, W. H., X. L., X. S.; validation, W. H., X. L., X. S.; formal analysis, W. H., X. L., X. S.; investigation, W. H., X. L., X. S.; resources, W. H., X. L., X. S.; data curation, W. H., X. L., X. S.; writing—original draft preparation, W. H., X. L., X. S.; writing—review and editing, W. H., X. L., X. S.; visualization, W. H., X. L., X. S.; supervision, W. H., X. L., X. S.; project administration, W. H., X. L., X. S.; funding acquisition, W. H., X. L., X. S. All authors have read and agreed to the published version of the manuscript.

Funding:

Not applicable.

Institutional Review Board Statement:

The studies were reviewed and approved by the Ethics Committee of the Eye Hospital, China Academy Of Chinese Medical Sciences.

Informed Consent Statement:

Written informed consent was obtained from all participants involved in this study, including consent for the publication of their clinical information and any accompanying images, where applicable.

Data Availability Statement:

Not applicable.

Conflict of Interest:

The authors declare no conflict of interest.

References

Berti, A., Boukhlal, S., Groh, M., & Cornec, D. (2020). Eosinophilic granulomatosis with polyangiitis: the multifaceted spectrum of clinical manifestations at different stages of the disease. Expert Review of Clinical Immunology, 16(1), 51-61.

Churg, J., & Strauss, L. (1951). Allergic granulomatosis, allergic angiitis, and periarteritis nodosa. The American journal of pathology, 27(2), 277.

Comarmond, C., Pagnoux, C., Khellaf, M., Cordier, J. F., Hamidou, M., Viallard, J. F., ... & French Vasculitis Study Group. (2013). Eosinophilic granulomatosis with polyangiitis (Churg - Strauss): clinical characteristics and long - term followup of the 383 patients enrolled in the French Vasculitis Study Group cohort. Arthritis & Rheumatism, 65(1), 270-281.

Cottin, V., Bel, E., Bottero, P., Dalhoff, K., Humbert, M., Lazor, R., ... & Cordier, J. F. (2016). Respiratory manifestations of eosinophilic granulomatosis with polyangiitis (Churg–Strauss). European Respiratory Journal, 48(5), 1429-1441.

Durel, C. A., Berthiller, J., Caboni, S., Jayne, D., Ninet, J., & Hot, A. (2016). Long-term followup of a multicenter cohort of 101 patients with eosinophilic granulomatosis with polyangiitis (Churg-Strauss). Arthritis care & research, 68(3), 374-387.

Fujimoto, S., Watts, R. A., Kobayashi, S., Suzuki, K., Jayne, D. R., Scott, D. G., ... & Nunoi, H. (2011). Comparison of the epidemiology of anti-neutrophil cytoplasmic antibody-associated vasculitis between Japan and the UK. Rheumatology, 50(10), 1916-1920.

Furuta, S., Iwamoto, T., & Nakajima, H. (2019). Update on eosinophilic granulomatosis with polyangiitis. Allergology International, 68(4), 430-436.

Hazebroek, M. R., Kemna, M. J., Schalla, S., Sanders-van Wijk, S., Gerretsen, S. C., Dennert, R., ... & Heymans, S. (2015). Prevalence and prognostic relevance of cardiac involvement in ANCA-associated vasculitis: eosinophilic granulomatosis with polyangiitis and granulomatosis with polyangiitis. International journal of cardiology, 199, 170-179.

Hinojosa-Azaola, A., García-Castro, A., Juárez-Flores, A., & Recillas-Gispert, C. (2019). Clinical significance of ocular manifestations in granulomatosis with polyangiitis: association with sinonasal involvement and damage. Rheumatology international, 39(3), 489-495.

Jennette, J. C., Falk, R. J., Bacon, P. A. (2013). 2012 revised international chapel hill consensus conference nomenclature of vasculitides. Arthritis Rheum, 65, 1-11.

Keogh, K. A., & Specks, U. (2006). Churg-Strauss syndrome. In Seminars in respiratory and critical care medicine, 27(02), 148-157.

Kitching, A. R., Anders, H. J., Basu, N., Brouwer, E., Gordon, J., Jayne, D. R., ... & Kain, R. (2020). ANCA-associated vasculitis. Nature reviews Disease primers, 6(1), 71.

Koike, H., Nishi, R., Ohyama, K., Morozumi, S., Kawagashira, Y., Furukawa, S., ... & Katsuno, M. (2022). ANCA-associated vasculitic neuropathies: a review. Neurology and Therapy, 11(1), 21-38.

Lanham, J. G., Elkon, K. B., Pusey, C. D., & Hughes, G. R. (1984). Systemic vasculitis with asthma and eosinophilia: a clinical approach to the Churg-Strauss syndrome. Medicine, 63(2), 65-81.

Lutalo, P. M., & D'Cruz, D. P. (2014). Diagnosis and classification of granulomatosis with polyangiitis (aka Wegener's granulomatosis). Journal of autoimmunity, 48, 94-98.

Moosig, F., Bremer, J. P., Hellmich, B., Holle, J. U., Holl-Ulrich, K., Laudien, M., ... & Gross, W. L. (2013). A vasculitis centre based management strategy leads to improved outcome in eosinophilic granulomatosis and polyangiitis (Churg − Strauss, EGPA): monocentric experiences in 150 patients. Annals of the rheumatic diseases, 72(6), 1011-1017.

Nevares, A., Raut, R., Libman, B., & Hajj-Ali, R. (2020). Noninfectious autoimmune scleritis: recognition, systemic associations, and therapy. Current Rheumatology Reports, 22, 1-10.

Raffray, L., & Guillevin, L. (2020). Updates for the treatment of EGPA. La Presse Médicale, 49(3), 104036.

Saku, A., Furuta, S., Hiraguri, M., Ikeda, K., Kobayashi, Y., Kagami, S. I., ... & Nakajima, H. (2018). Longterm outcomes of 188 Japanese patients with eosinophilic granulomatosis with polyangiitis. The Journal of Rheumatology, 45(8), 1159-1166.

Sinico, R. A., Di Toma, L., Maggiore, U., Bottero, P., Radice, A., Tosoni, C., ... & Buzio, C. (2005). Prevalence and clinical significance of antineutrophil cytoplasmic antibodies in Churg-Strauss syndrome. Arthritis & Rheumatism, 52(9), 2926-2935.

Szczeklik, W., Sokołowska, B. M., Żuk, J., Mastalerz, L., Szczeklik, A., & Musiał, J. (2011). The course of asthma in Churg–Strauss syndrome. Journal of Asthma, 48(2), 183-187.

Tsurikisawa, N., Oshikata, C., Kinoshita, A., Tsuburai, T., & Saito, H. (2017). Longterm prognosis of 121 patients with eosinophilic granulomatosis with polyangiitis in Japan. The Journal of Rheumatology, 44(8), 1206-1215.

Turk, M. A., Hayworth, J. L., Nevskaya, T., & Pope, J. E. (2021). Ocular manifestations in rheumatoid arthritis, connective tissue disease, and vasculitis: a systematic review and metaanalysis. The Journal of Rheumatology, 48(1), 25-34.

Vergouwen, D. P. C., Rothová, A., Ten Berge, J. C., Verdijk, R. M., van Laar, J. A. M., Vingerling, J. R., & Schreurs, M. W. J. (2020). Current insights in the pathogenesis of scleritis. Experimental Eye Research, 197, 108078.

Watanabe, R., & Hashimoto, M. (2023). Eosinophilic granulomatosis with polyangiitis: latest findings and updated treatment recommendations. Journal of Clinical Medicine, 12(18), 5996.

Wechsler, M. E., Akuthota, P., Jayne, D., Khoury, P., Klion, A., Langford, C. A., ... & Gleich, G. J. (2017). Mepolizumab or placebo for eosinophilic granulomatosis with polyangiitis. New England Journal of Medicine, 376(20), 1921-1932.